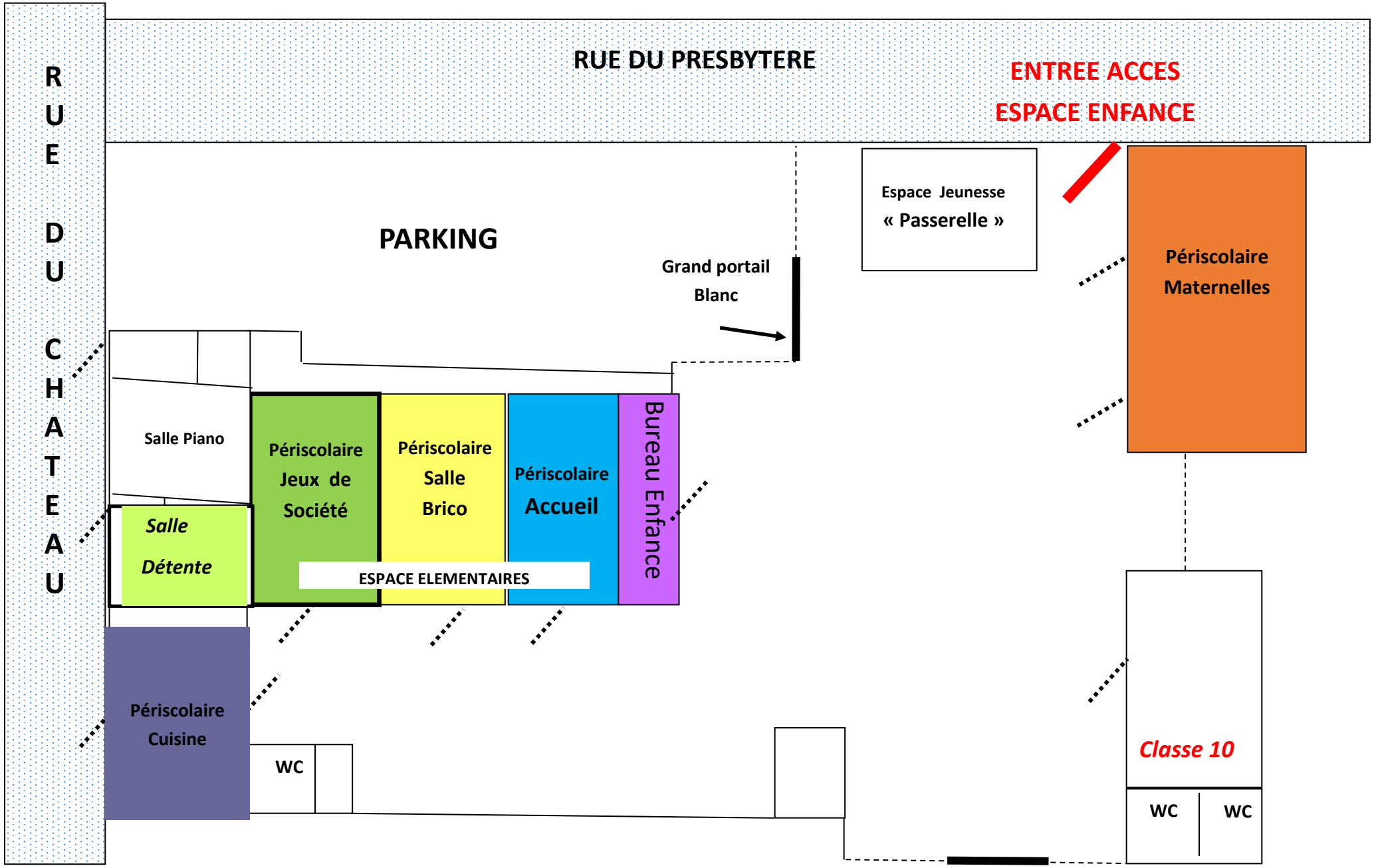ACCUEIL PERISCOLAIRE ET ALSH